

Test Your Skills—A question and answer book to prepare for the Certification Board of Cardiovascular Computed Tomography Exam

SCCT Cardiovascular CT Board Prep

450 Practice Questions with Answers and Explanations to Help You Master the Exam

EDITORS: Stephan Achenbach, MD, Armin Arbab-Zadeh, MD, Ricardo C. Cury, MD, Michael Poon, MD, Wm. Guy Weigold, MD

CONTRIBUTING AUTHORS:

Stephan Achenbach, MD, Armin Arbab-Zadeh, MD, Lawrence M. Boxt, MD, David E. Bush, MD, Ricardo C. Cury, MD, Jonathan D. Dodd, MD, Gudrun Feuchtner, MD, Michael Poon, MD, Edward P. Shapiro, MD, Michael D. Shapiro, DO, Wm. Guy Weigold, MD

- The SCCT Cardiovascular CT Board Prep book contains hundreds of questions, figures and images, with complete explanations of answers.
- This invaluable resource represents the largest collection of cardiovascular CT review questions compiled in any one source.
- This book is written and edited by experts from the SCCT, the authority in cardiovascular CT education.
- Nine sections, plus a practice test cover the topics that will be encountered on the exam. The quantity and distribution of subjects are designed to represent each section according to the CBCCT exam blueprint.

SECTIONS INCLUDE:

- | | | |
|--------------------------------------|---------------------------------------|--|
| 1. Radiation and Radiation Safety | 4. Image Acquisition and Protocols | 7. Coronary Arteries, including CABG and Stent CTA |
| 2. Computed Tomography Fundamentals | 5. Reconstruction and Post-Processing | 8. Non-Coronary Cardiac |
| 3. Patient Selection and Preparation | 6. Artifacts | 9. Non-Cardiac |

PLUS—A Practice Examination!



- Member \$199 Nonmember \$249
 Standard Shipping \$8.00 Standard 2-Day Shipping \$25.99

Name _____ Email _____

Shipping Address _____

Billing Information

- Enclosed is a check (USD) made payable to the SCCT
 Credit card information is as follows:
 Visa MasterCard American Express Discover

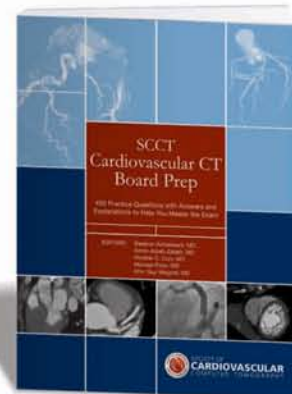
Card # _____

Expiration Date _____ CVV Code _____

Billing Address _____

City _____ State/Province _____ Postal code _____ Country _____

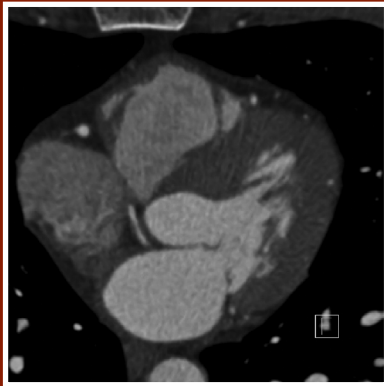
Signature _____



Your credit card will not be billed until day of shipment

Fax your order to: 1-888-849-1542
For international rates, please call 703-766-1706
www.scct.org

Question: This image is very typical for which of the following:

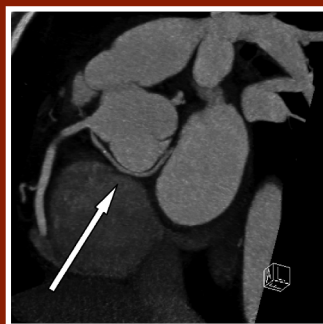
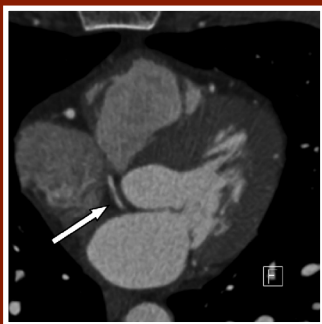


- A- Aortic dissection
- B- Left ventricular noncompaction
- C- Pulmonary hypertension
- D- Anomalous course of left circumflex coronary artery

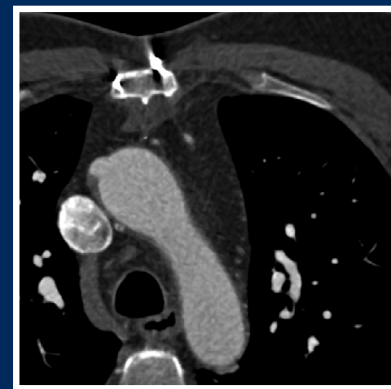Correct answer: D

DISCUSSION:

This is the typical image of an anomalous left circumflex coronary artery arising from the right coronary sinus and coursing behind and below the aortic root.



Question: Based on this image, the previous coronary bypass procedure is most likely to have been which of the following:



- A- One arterial (IMA) graft and at least one vein graft
- B- Two arterial grafts (IMA) and at least one vein graft
- C- No arterial grafts and at least two vein grafts
- D- At least three vein grafts

Correct answer: B

DISCUSSION:

There are no vessels in the chest wall adjacent to either border of the sternum, indicating that both internal mammary arteries have been used as arterial grafts (see arrows in image below). Also, one vein graft anastomosis (in a somewhat atypical position) can be seen (arrowhead).

